Robert Wood Johnson Foundation

Duke University
School of Medicine

University of Michigan
Medical School

Stanford | MEDICINE

University of California
San Francisco

UW Medicine
SCHOOL OF MEDICINE

Acute Gastrointestinal Infections

Enteric Fever

Manuel R. Amieva, M.D., Ph.D.
Department of Pediatrics, Infectious Diseases
Department of Microbiology & Immunology
Stanford University School of Medicine

Sharon F. Chen, M.D.
Department of Pediatrics, Infectious Diseases
Stanford University School of Medicine

CC BY NC ND

Learning Objectives

- Describe the clinical presentation, epidemiology, pathogenesis, complications and treatment of enteric fever due to *Salmonella enterica* serovar Typhi
- Explain why *S*. Typhi causes fever of unknown origin and not gastroenteritis
- Explain the concept of asymptomatic carriage
- Discuss how the gastrointestinal tract serves as a portal of entry for other microbes that cause systemic disease

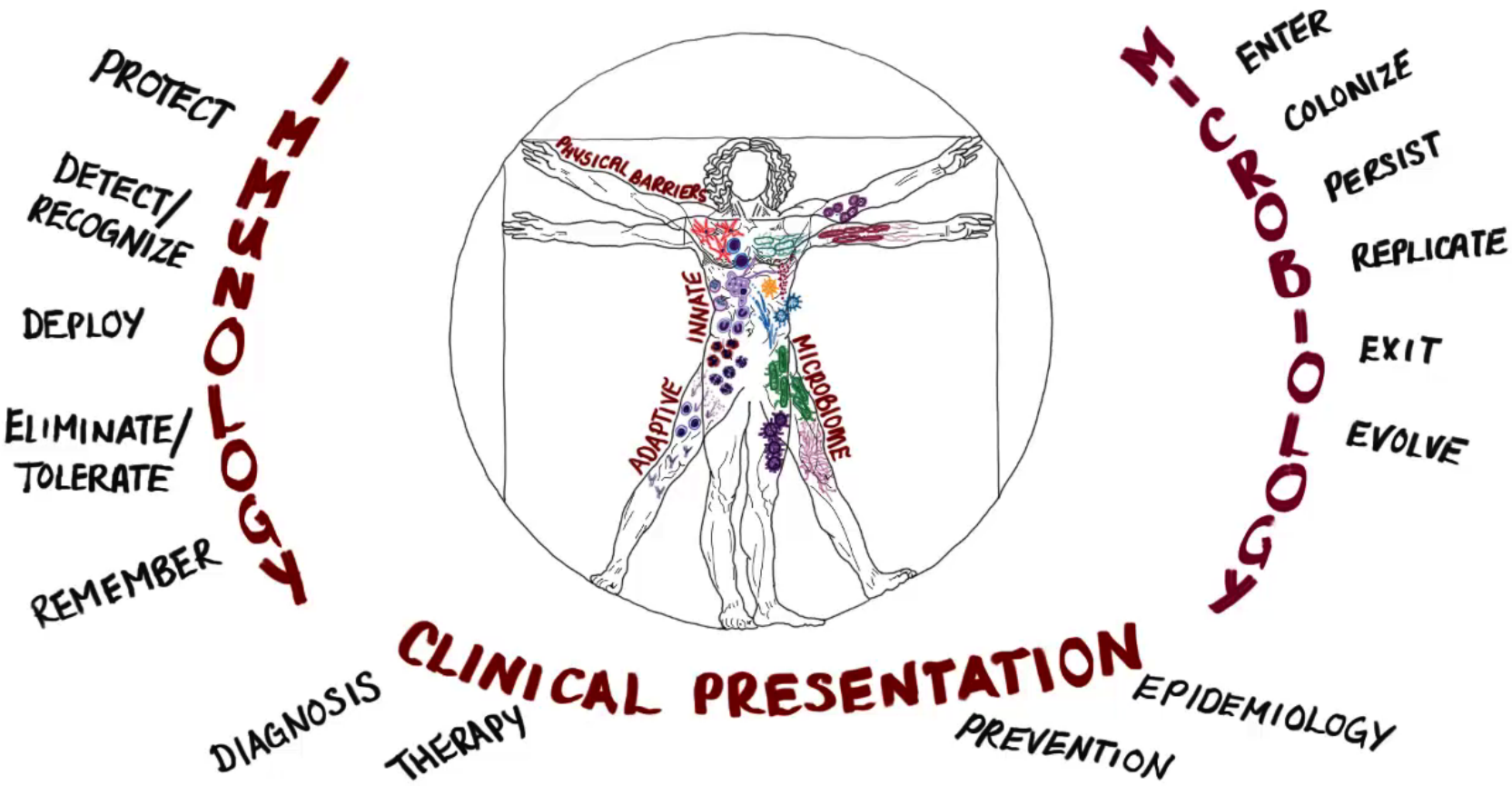
IMMUNOLOGY
PROTECT
DETECT/ RECOGNIZE
DEPLOY
ELIMINATE/ TOLERATE
REMEMBER
PHYSICAL BARRIERS
INNATE
ADAPTIVE
MICROBIOME
MICROBIOLOGY
ENTER
COLONIZE
PERSIST
REPLICATE
EXIT
EVOLVE
CLINICAL PRESENTATION
DIAGNOSIS
THERAPY
PREVENTION
EPIDEMIOLOGY

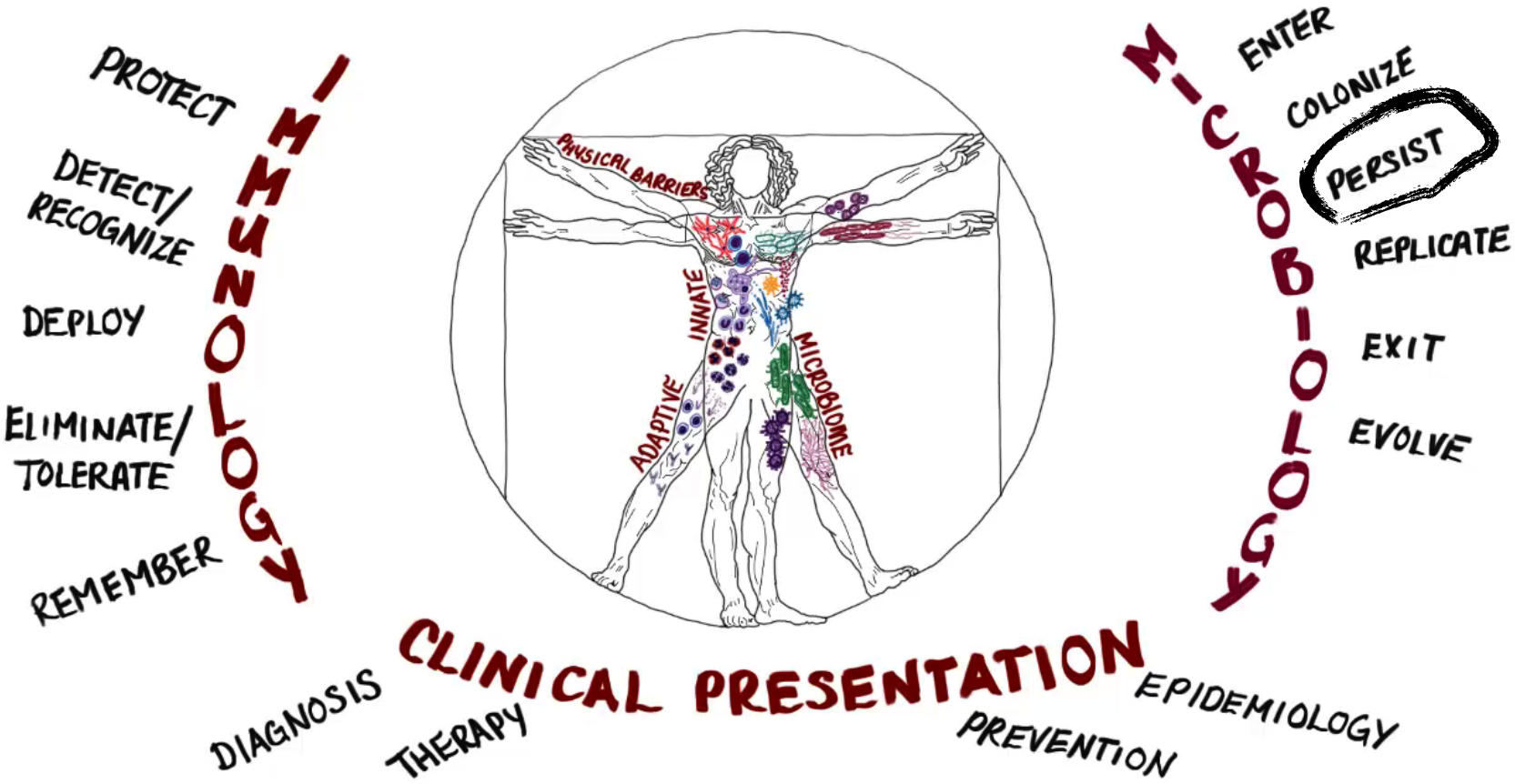
IMMUNOLOGY
PROTECT
DETECT/ RECOGNIZE
DEPLOY
ELIMINATE/ TOLERATE
REMEMBER
PHYSICAL BARRIERS
INNATE
ADAPTIVE
MICROBIOME
MICROBIOLOGY
ENTER
COLONIZE
PERSIST
REPLICATE
EXIT
EVOLVE
CLINICAL PRESENTATION
DIAGNOSIS
THERAPY
PREVENTION
EPIDEMIOLOGY

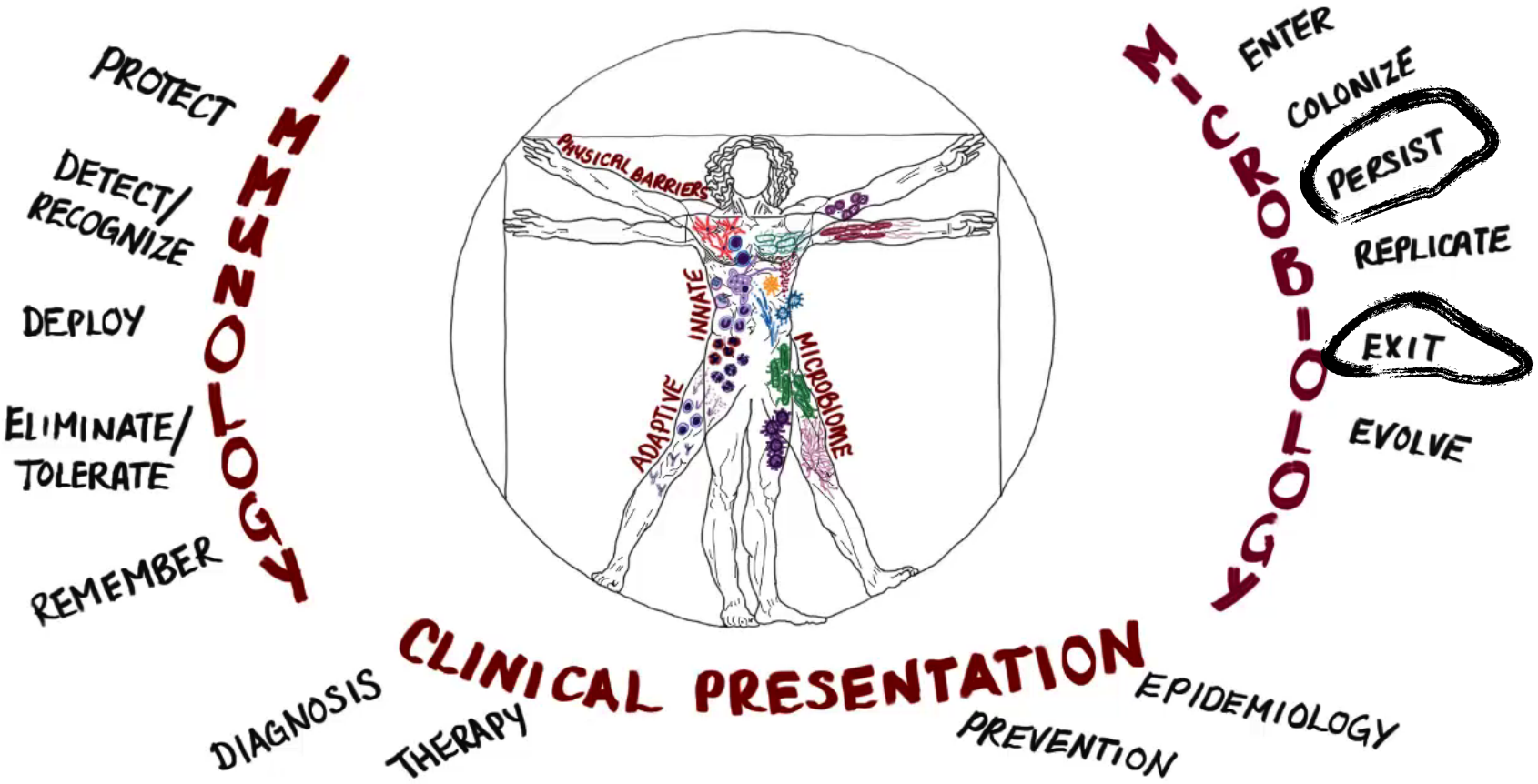
IMMUNOLOGY
PROTECT
DETECT/ RECOGNIZE
DEPLOY
ELIMINATE/ TOLERATE
REMEMBER
PHYSICAL BARRIERS
INNATE
ADAPTIVE
MICROBIOME
MICROBIOLOGY
ENTER
COLONIZE
PERSIST
REPLICATE
EXIT
EVOLVE
CLINICAL PRESENTATION
DIAGNOSIS
THERAPY
PREVENTION
EPIDEMIOLOGY

Enteric Fever

Clinical Features	Prolonged **fever of unknown origin** with chills, hepatosplenomegaly, ± constipation, ±rose spots
Complications	Bowel perforation, osteomyelitis, septic arthritis, meningitis, chronic carriage
Management	**Blood cultures** essential. Stool cultures may be negative. Requires antibiotic therapy
Anatomical Location	**Systemic disease**
Pathogenesis	Spread systemically, survives in macrophages, may reseed the bowel and transmit through feces. Survives in lymph nodes, liver, spleen, bone marrow, gall bladder
Viruses	none
Bacteria	***Salmonella* Typhi** and Paratyphi (other systemic invasive enteropathogens- *Listeria, Brucella,* non-Typhi *Salmonella, Yersinia)*
Protozoa	none

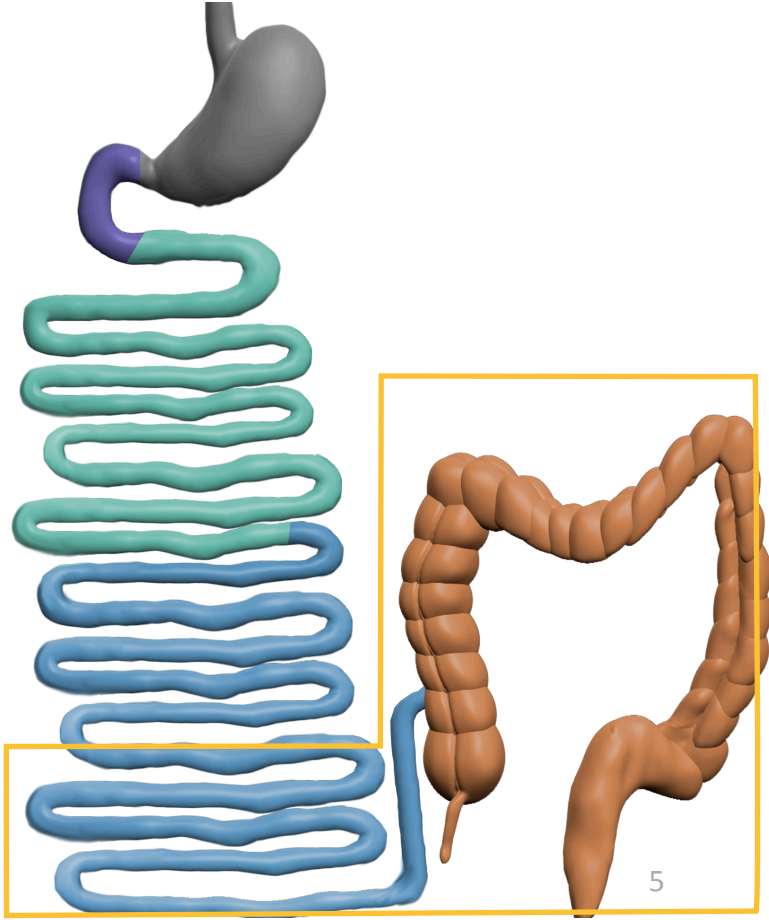

Enteric Fever

Clinical Features	Prolonged **fever of unknown origin** with chills, hepatosplenomegaly, ± constipation, ±rose spots
Complications	Bowel perforation, osteomyelitis, septic arthritis, meningitis, chronic carriage
Management	**Blood cultures** essential. Stool cultures may be negative. Requires antibiotic therapy
Anatomical Location	**Systemic disease**
Pathogenesis	Spread systemically, survives in macrophages, may reseed the bowel and transmit through feces. Survives in lymph nodes, liver, spleen, bone marrow, gall bladder
Viruses	none
Bacteria	***Salmonella* Typhi** and Paratyphi (other systemic invasive enteropathogens- *Listeria, Brucella,* non-Typhi *Salmonella, Yersinia)*
Protozoa	none

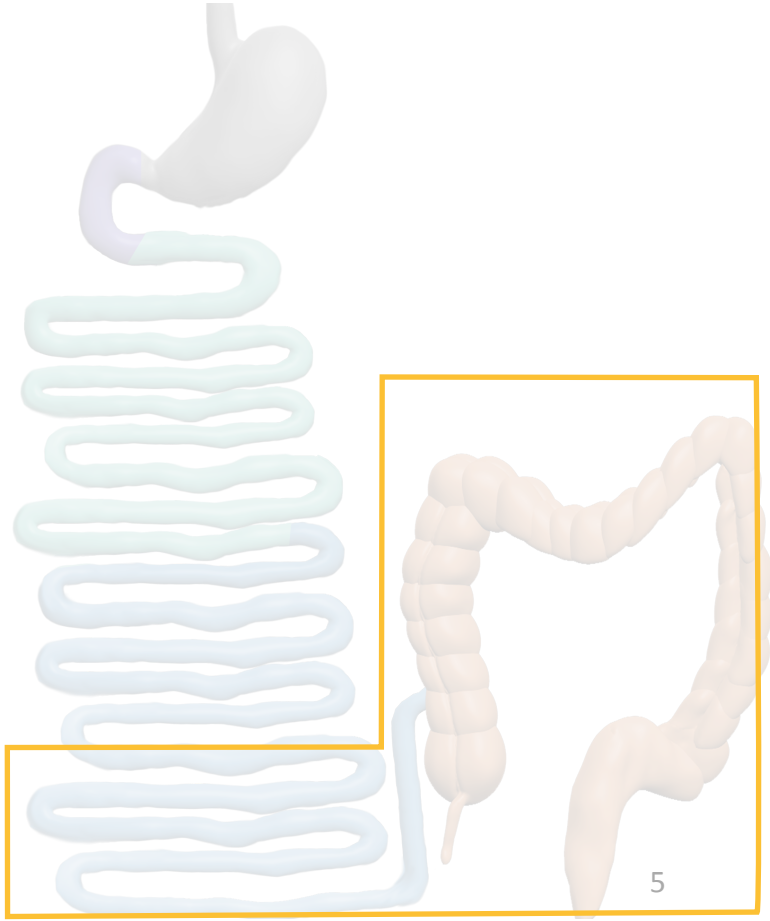

Enteric fever - Typhoid fever

- *Salmonella enterica* serovar Typhi or Paratyphi
  - Some new strains of *S.* Typhimurium in Africa emerging
- 20 million cases per year, 500,000 deaths
- Fecal-oral transmission - contaminated water and food
- Humans are the only reservoir; 1-4% chronic carriers
- Fatality rate is 20-30% if untreated, 1% with appropriate antibiotic treatment

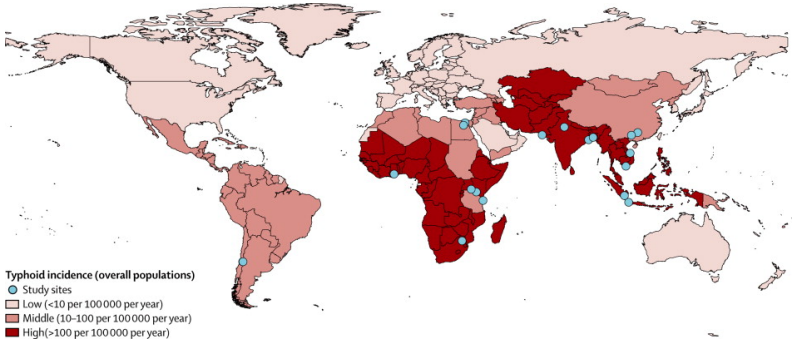

Enteric fever - Clinical characteristics

- 7-10 day incubation
- Insidious onset
  - Rising fever, malaise, headache, myalgia
- Several weeks of duration
  - Sustained high fever after three weeks
  - Hepatosplenomegaly, ±abdominal pain, ±constipation/diarrhea
  - Mild rash in 30%- rose spots
- Positive Blood Cultures
  - +/- Stool Cultures
- Elevated liver enzymes, ± leukopenia, thrombocytopenia, anemia

Enteric fever - Late stages

- Delirium, “stupor”,
- More serious complications arise in 3rd-4th week
  - Intestinal perforation sepsis and death
  - Meningitis
  - Bone and joint infections
  - Endocarditis

Enteric fever - Late stages

- Delirium, “stupor”,
- More serious complications arise in 3rd-4th week
  - Intestinal perforation sepsis and death
  - Meningitis
  - Bone and joint infections
  - Endocarditis

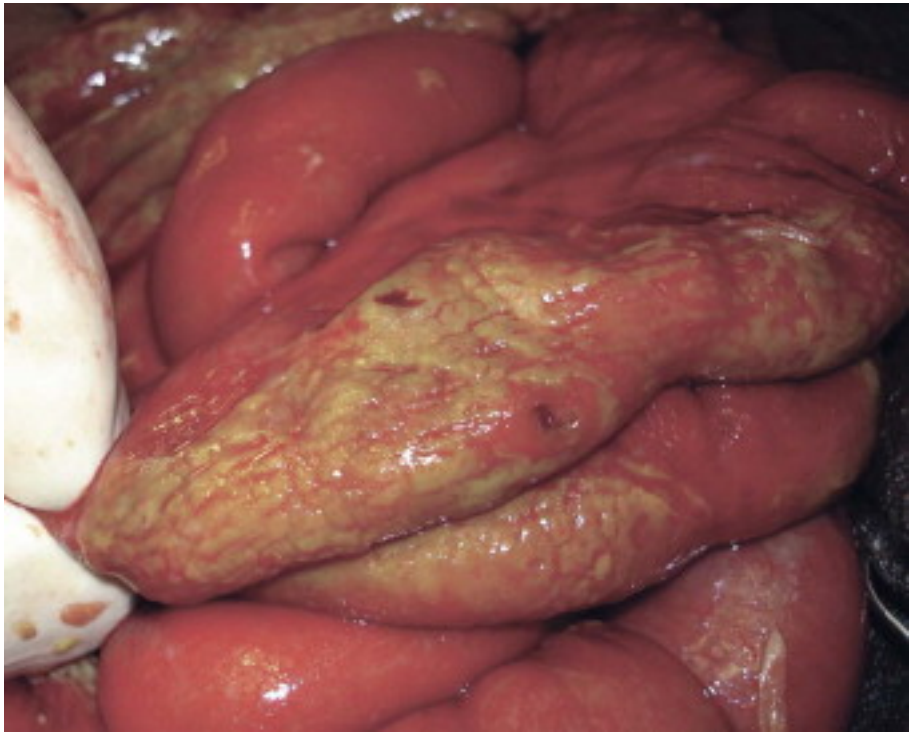

S. Typhi Pathogenesis

Salmonella invades through M-cells in the Peyer's patches by injecting effectors through a T3SS.

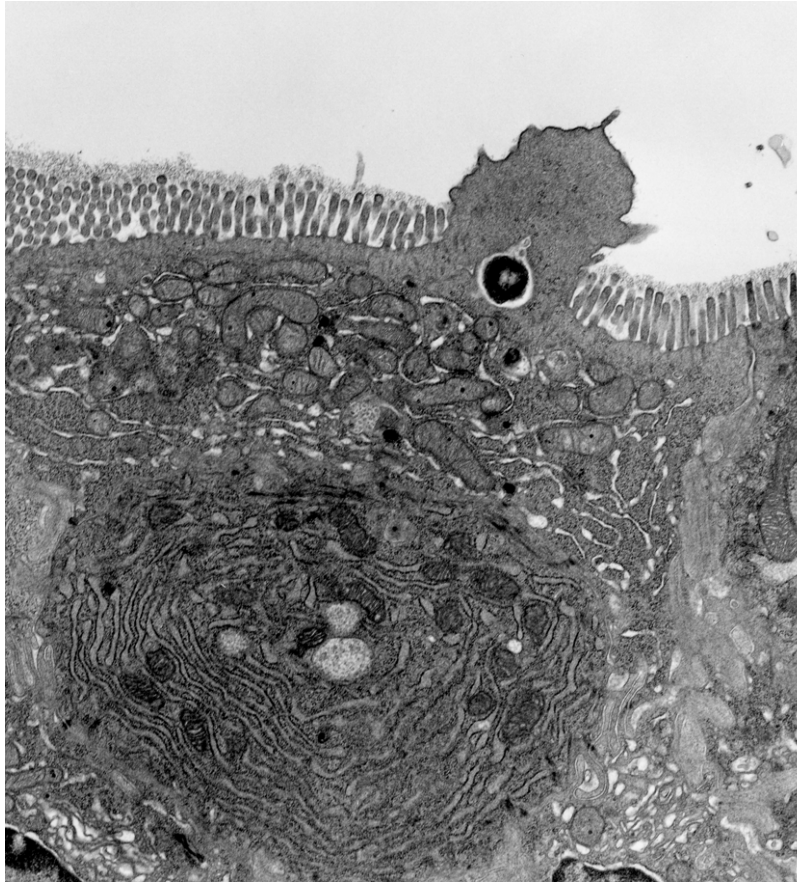

S. Typhi Pathogenesis

- **Under the M-cells are cells of the immune system like macrophages and dendritic cells**
- *Salmonella* can survive in these cells and even move through the body inside them.

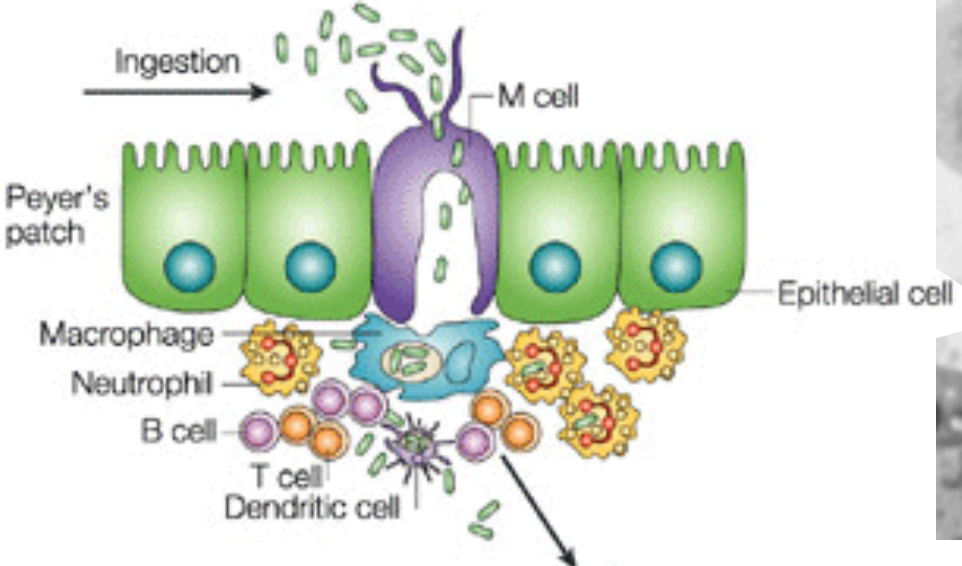

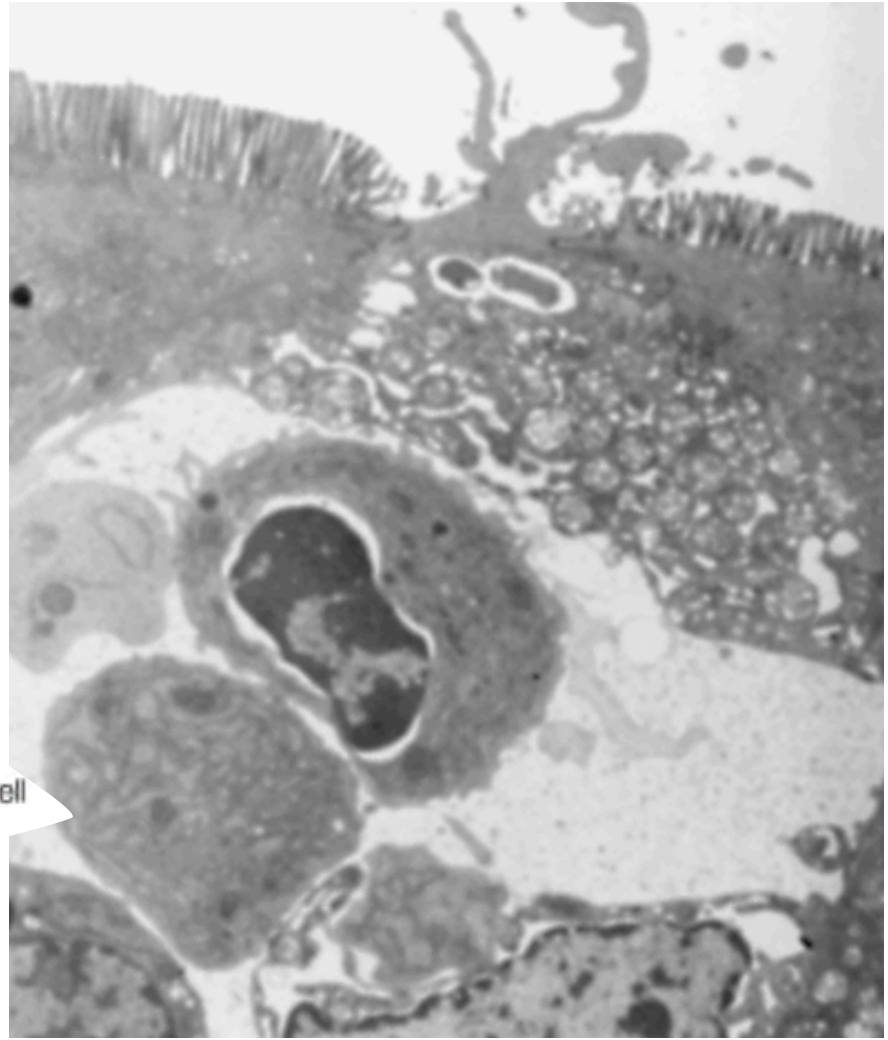

S. Typhi Pathogenesis

- **Under the M-cells are cells of the immune system like macrophages and dendritic cells**
- *Salmonella* can survive in these cells and even move through the body inside them.

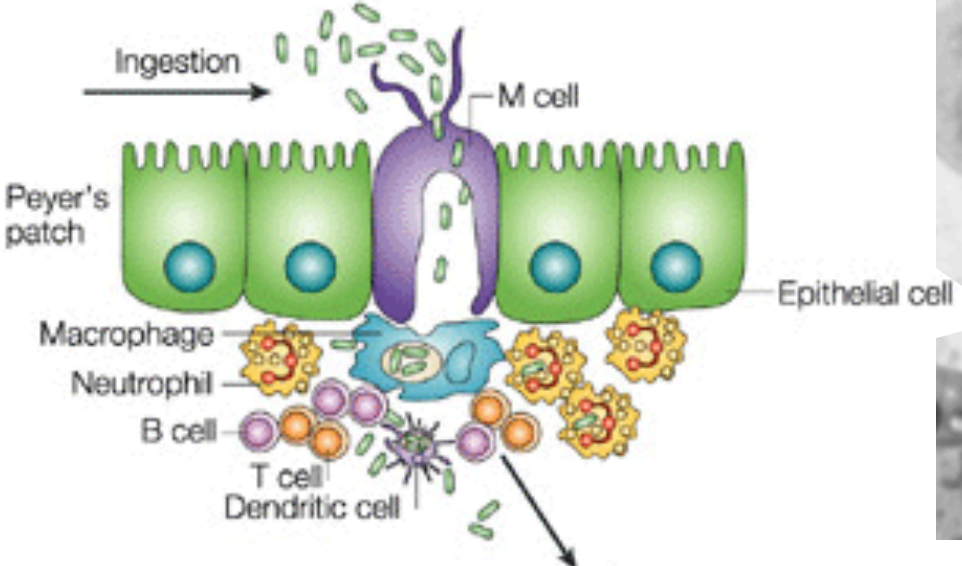

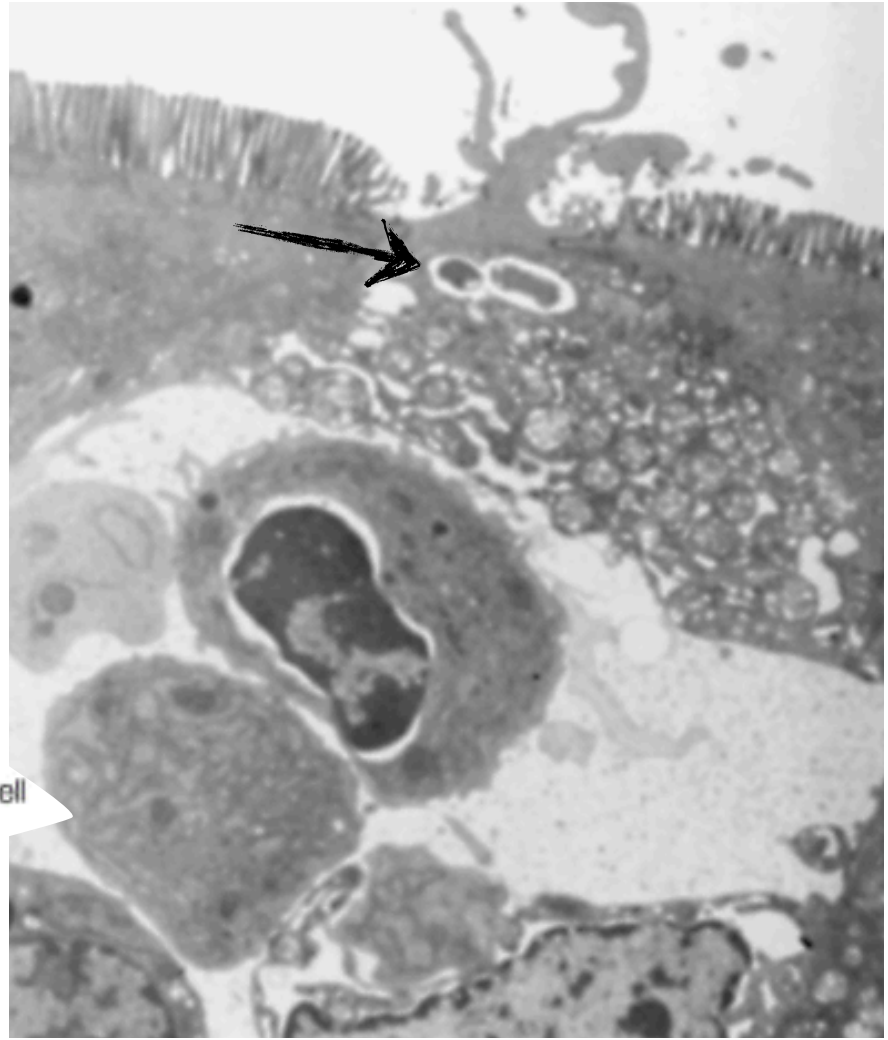

S. Typhi Pathogenesis

•Once inside a host cell vacuole, *S*. Typhi uses a second T3SS to inject effectors into the cytosol that will help it survive.

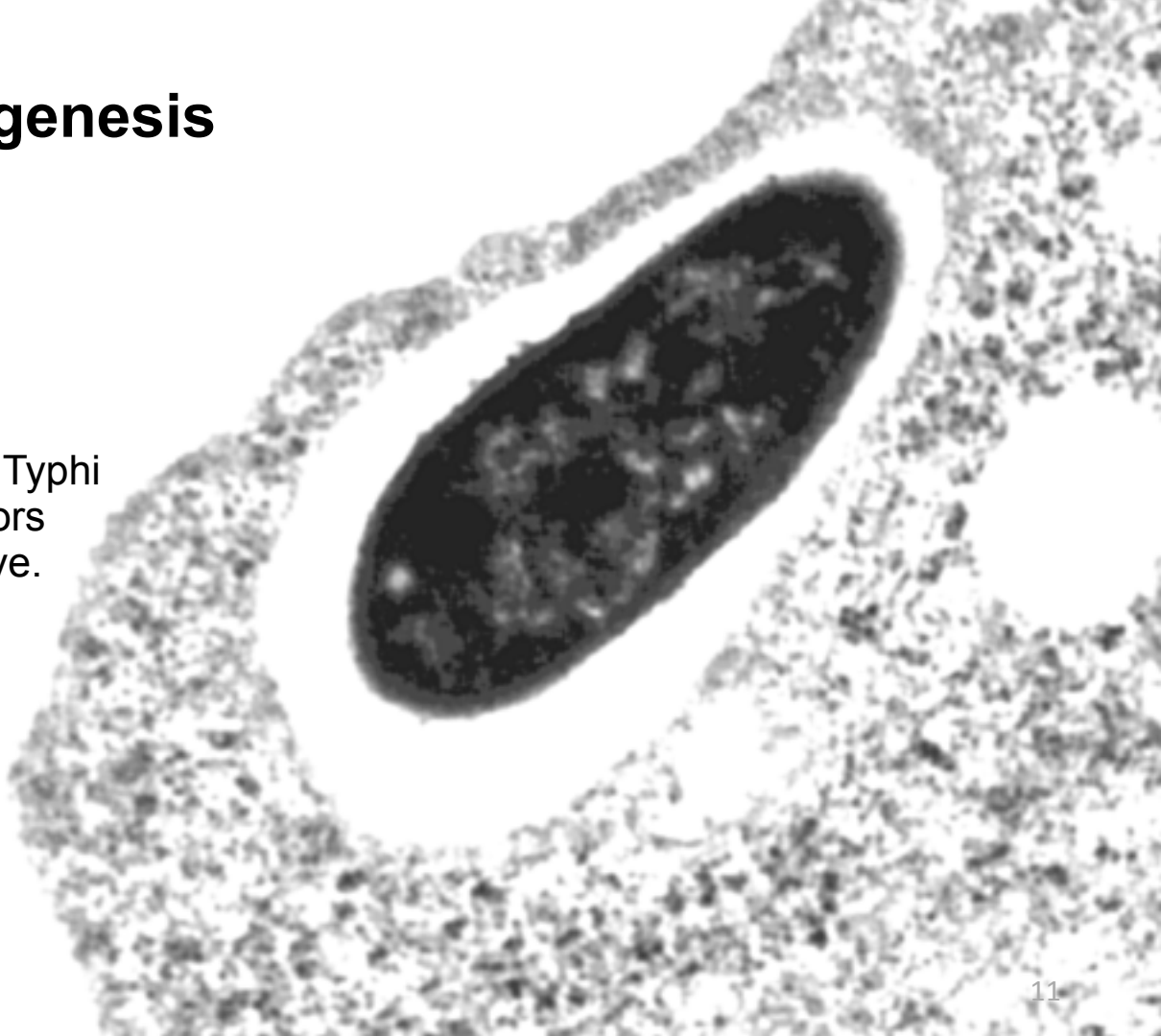

S. Typhi Pathogenesis

•Once inside a host cell vacuole, *S*. Typhi uses a second T3SS to inject effectors into the cytosol that will help it survive.

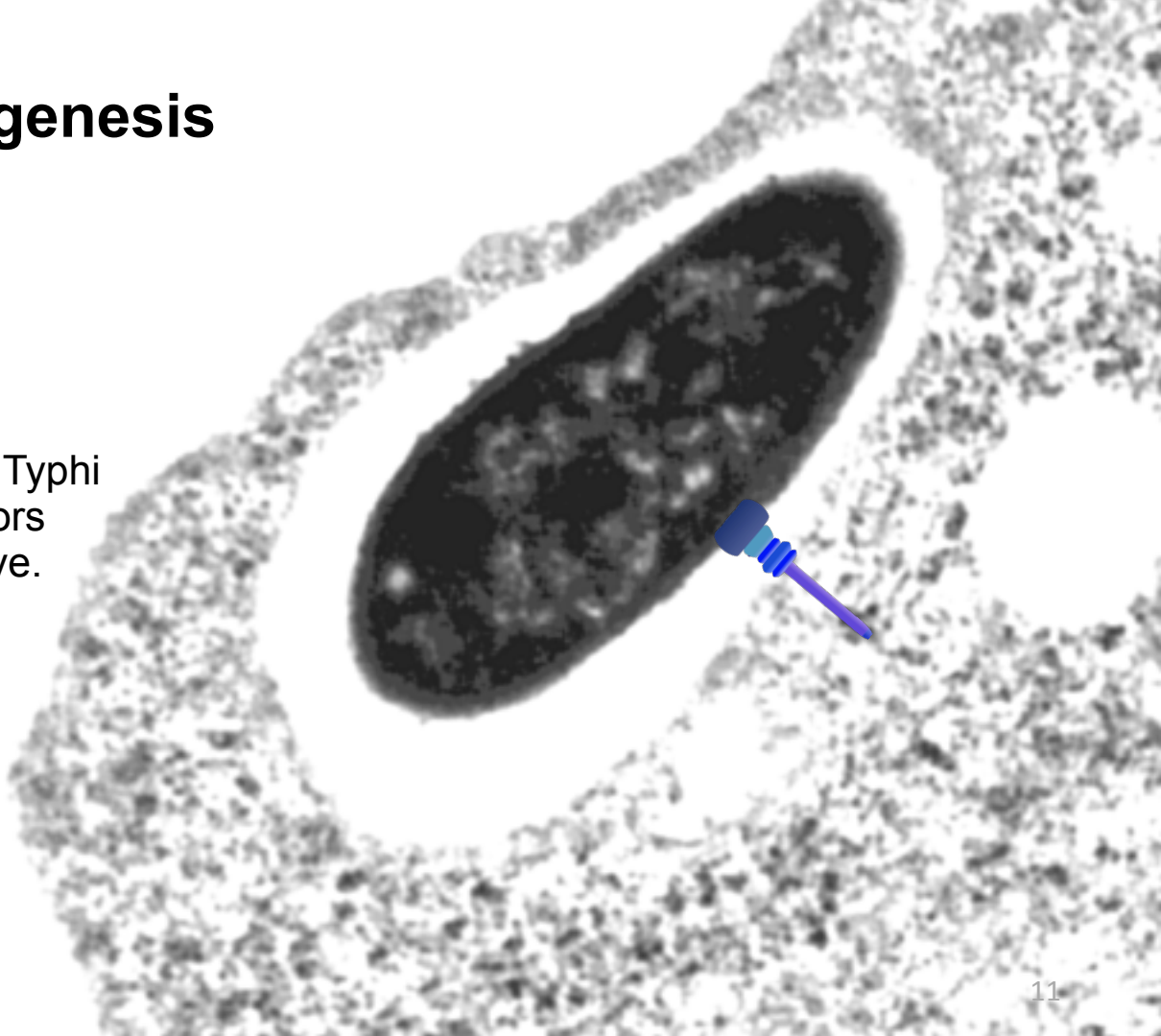

S. Typhi Pathogenesis

•Once inside a host cell vacuole, *S*. Typhi uses a second T3SS to inject effectors into the cytosol that will help it survive.

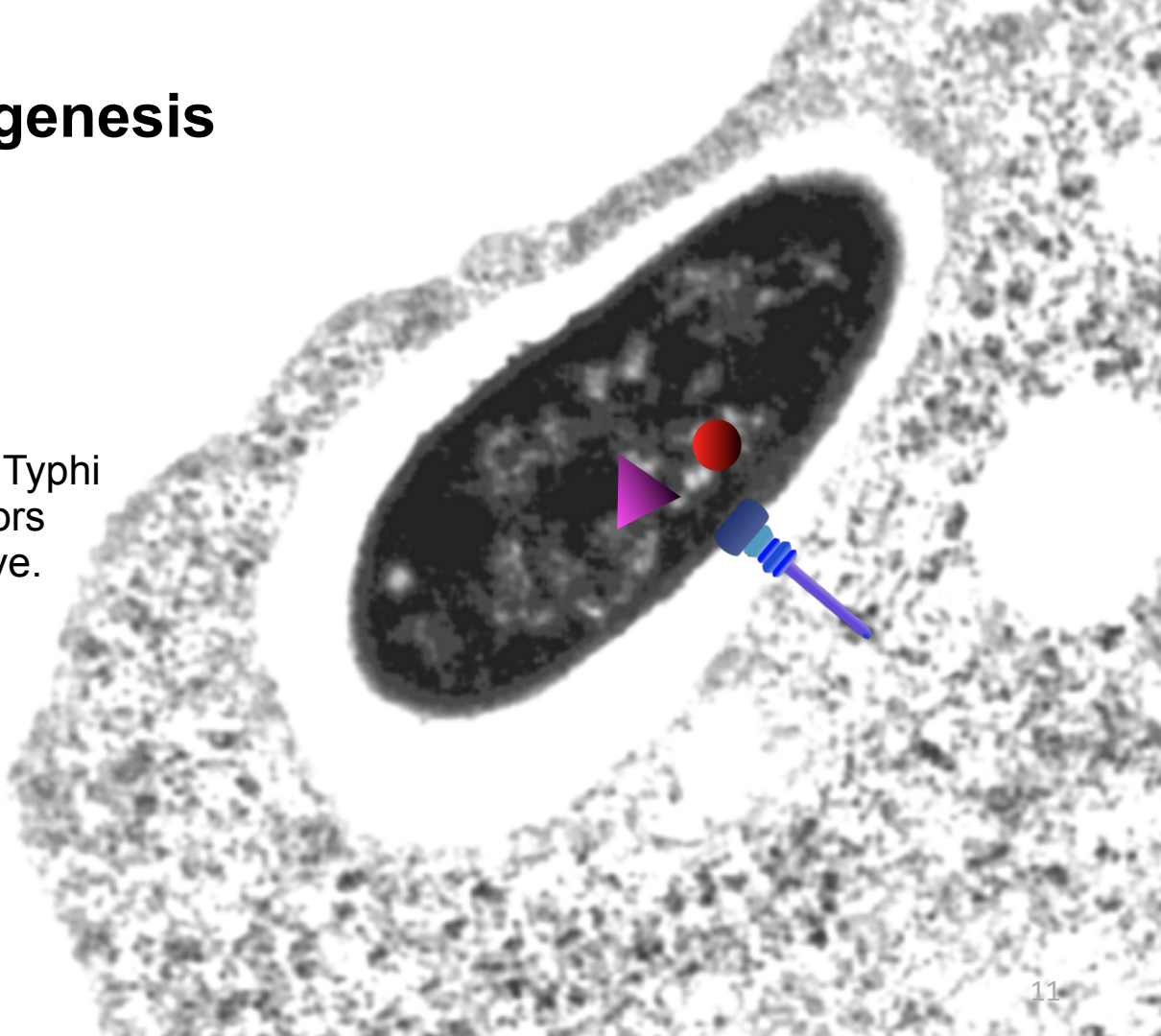

S. Typhi Pathogenesis

•Once inside a host cell vacuole, *S*. Typhi uses a second T3SS to inject effectors into the cytosol that will help it survive.

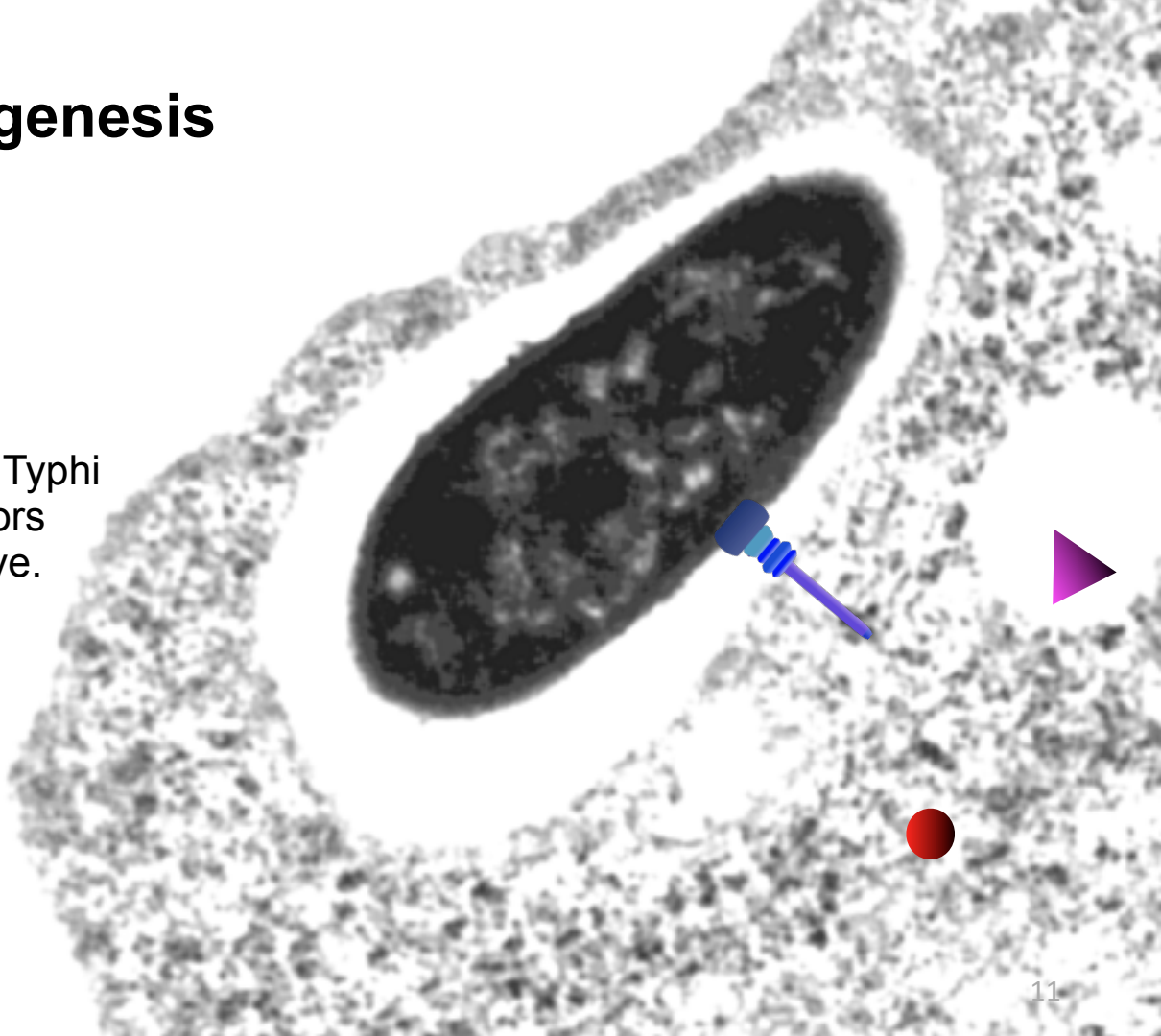

S. Typhi Pathogenesis

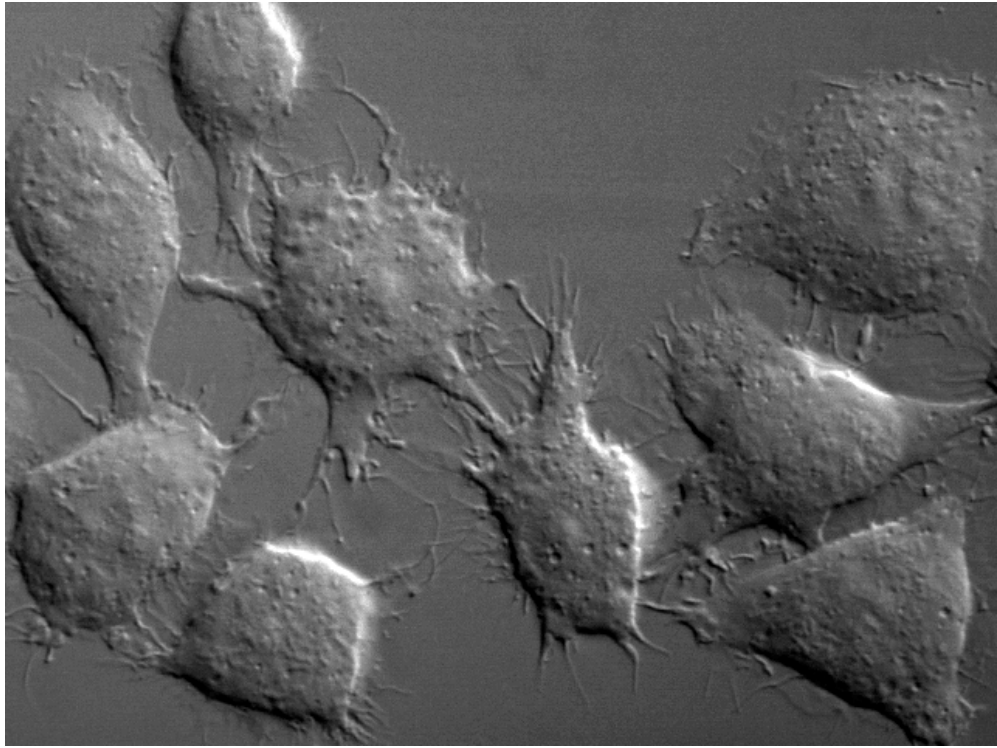

- *Salmonella* can survive in these cells and even move through the body inside them.

S. Typhi Pathogenesis

- *Salmonella* can survive in these cells and even move through the body inside them.
- It travels to the local mesenteric lymph nodes and then to
    - bone marrow
    - spleen

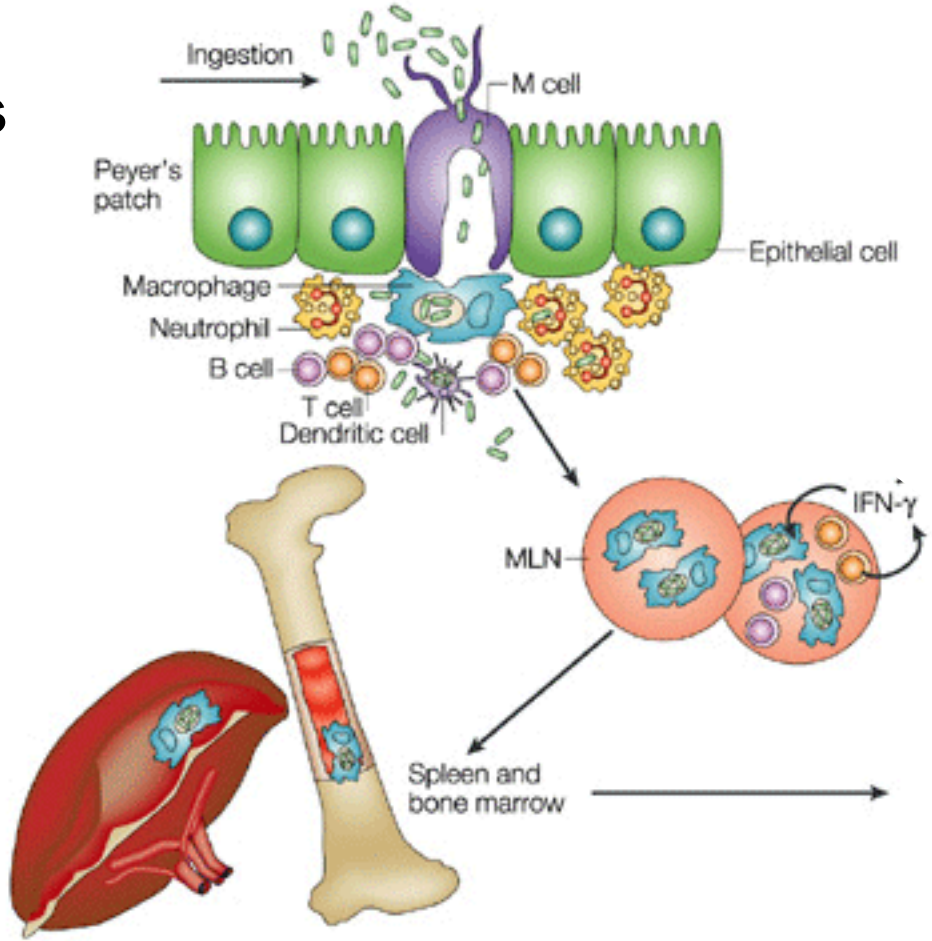

S. Typhi Pathogenesis

- *Salmonella* can survive in these cells and even move through the body inside them.
- It travels to the local mesenteric lymph nodes and then to
  - bone marrow
  - spleen

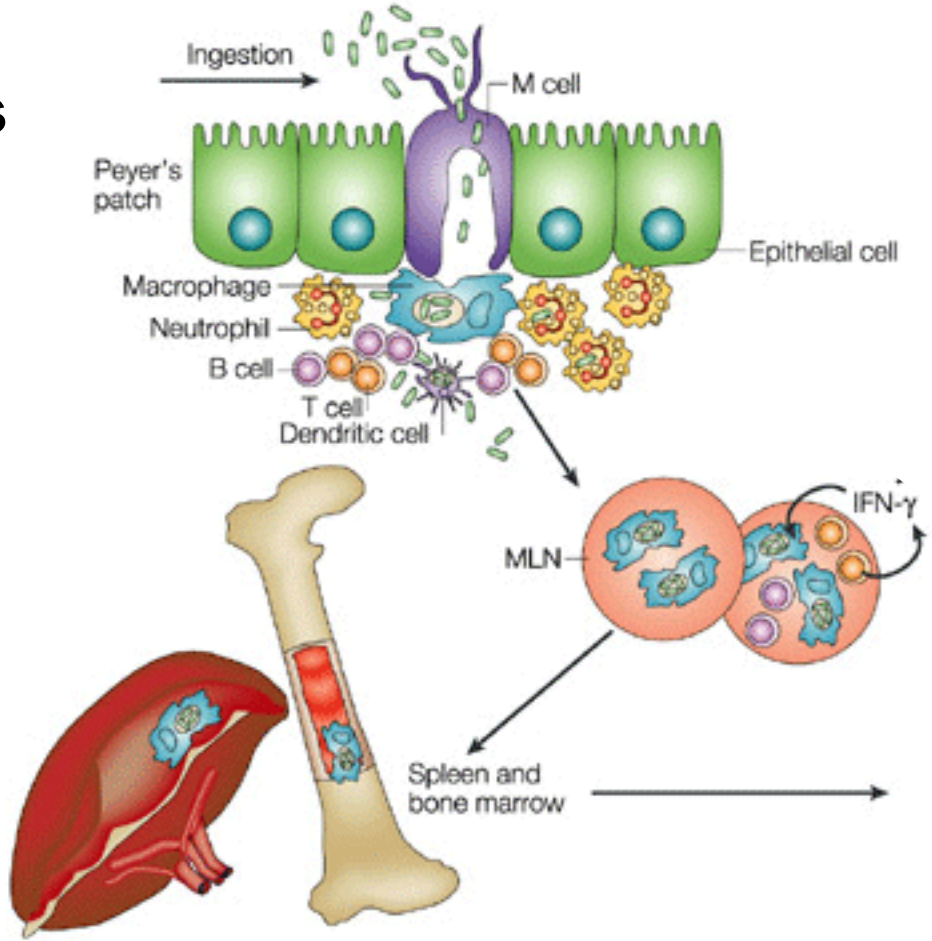

S. Typhi Pathogenesis

- *Salmonella* can survive in these cells and even move through the body inside them.
- It travels to the local mesenteric lymph nodes and then to
    - bone marrow
    - spleen
    - liver

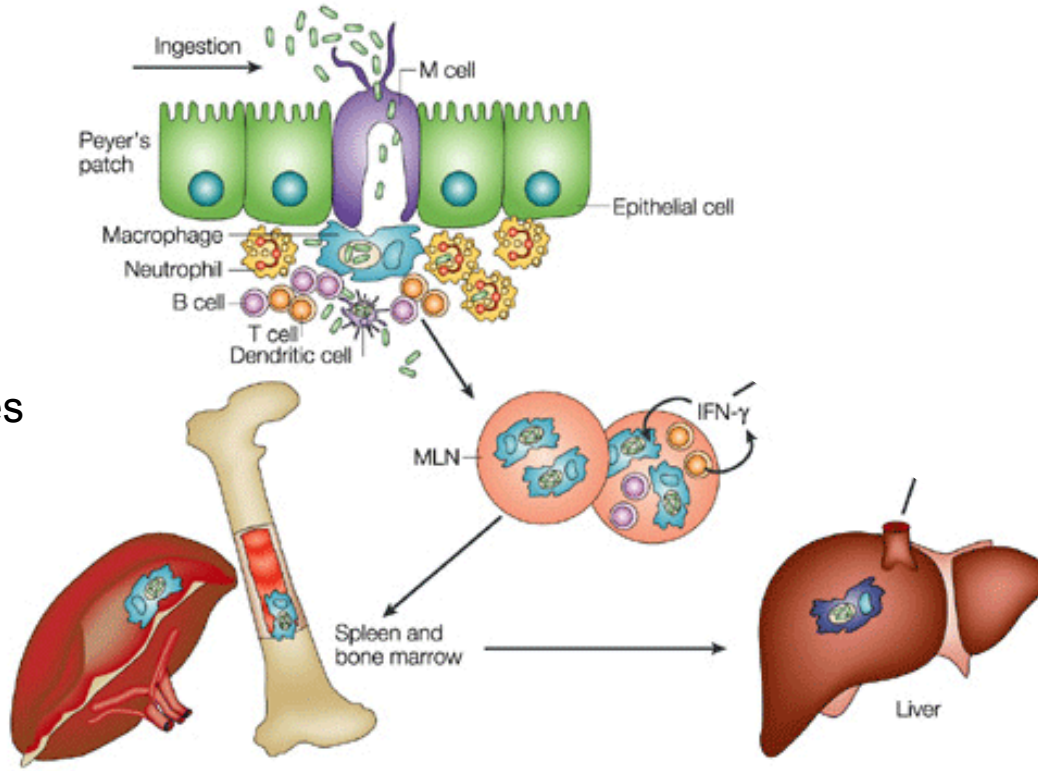

S. Typhi Pathogenesis

•*Salmonella* is thought to migrate back out into the gut lumen by invading the gall bladder epithelium and being shed in the bile

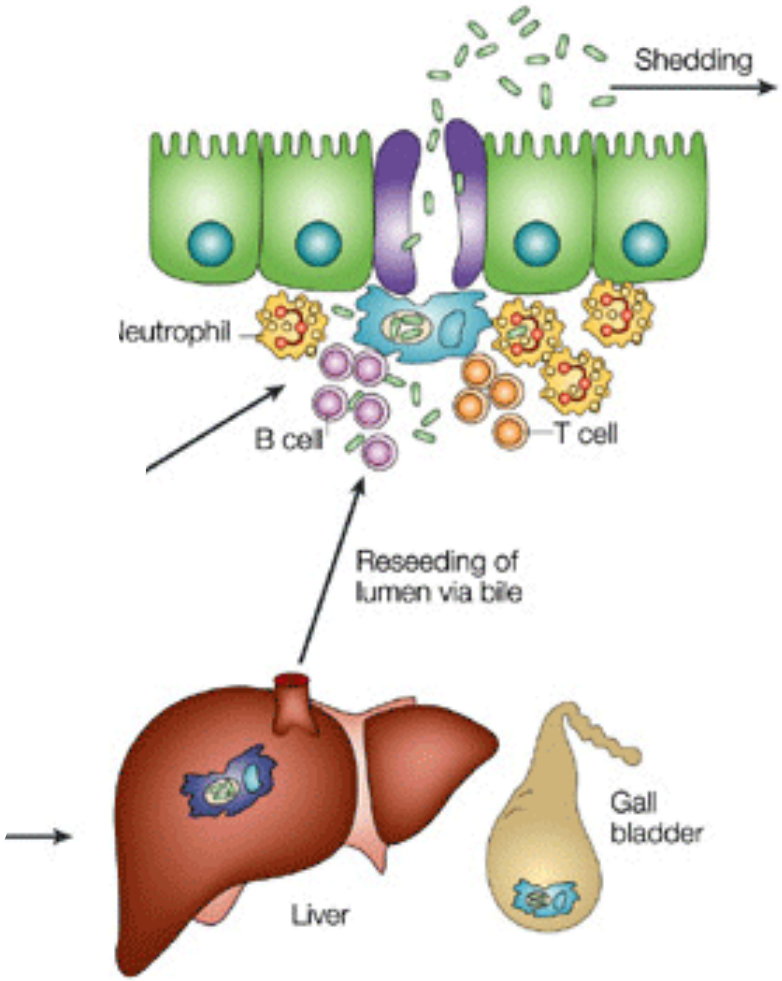

S. Typhi chronic carriage

- Up to 10% of those who recover from Enteric Fever continue to excrete *Salmonella* in the feces sporadically for years.
- They are the reservoirs of the infection.
- Typhoid Mary
  - Mary Mallon, an Irish immigrant and cook in NY, was the first known *S*. Typhi carrier in the U.S. She was arrested in 1907 quarantined for 23 years because she had previously infected 47 people (3 of whom died).

S. Typhi Treatment

- This infection needs to be treated with appropriate antibiotics
- Blood cultures are important for diagnosis and also to determine antibiotic susceptibility

Can we prevent Enteric Fever?

- Public health measures are essential.
- Two vaccines are available
  - Ty21a- a live attenuated vaccine
  - Vi capsular polysaccharide vaccine
  - Neither work very well in children and protection wanes

Other invasive enteric pathogens

- *Brucella* sp
- *Yersinia enterocolitica*
- *Yersinia pseudotuberculosis*
- *Listeria monocytogenes*

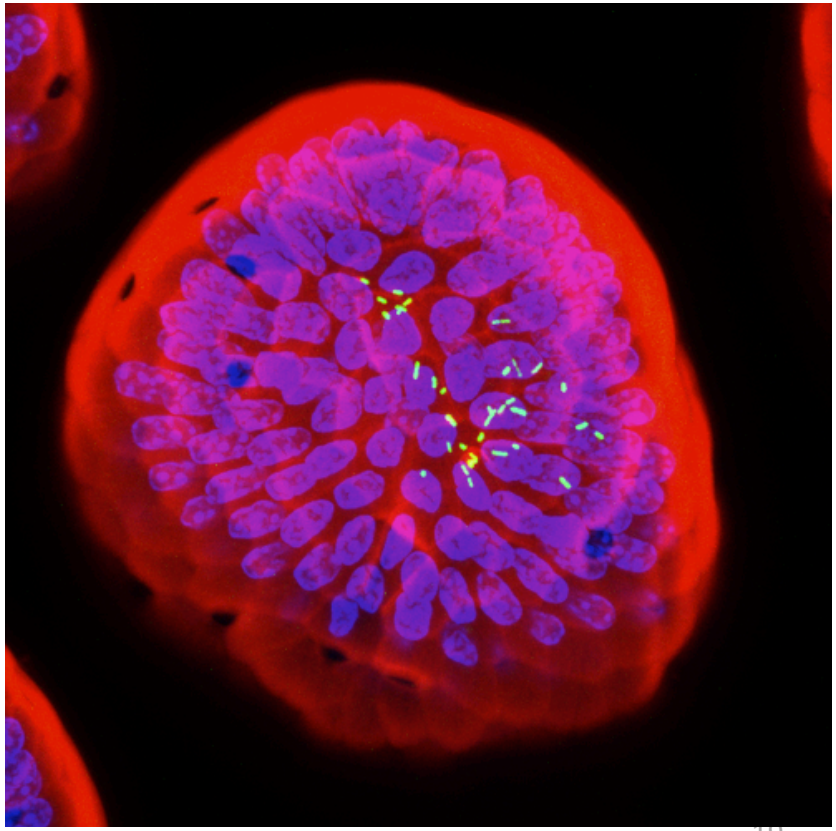

Credits: Enteric Fever

Slide 6: Burden of typhoid fever in low-income and middle-income countries: a systematic, literature-based update with risk-factor adjustment.
https://www.clinicalkey.com

Slide 7: Typhoid fever trailer clip from: PBS NOVA- Typhoid Mary. The most dangerous woman in America.

Slide 8: Intraoperative photograph of intestinal perforation caused by *S*. Typhi. Intestinal perforation is seen on the antimesenteric border of the small bowel, which is inflamed with patchy exudates on the serosal surface. (Courtesy Dr. Pukar Maskey, Patan Hospital, Katmandu, Nepal. From Harris JB, Brooks WA. Typhoid and paratyphoid (enteric) fever. In Magill AJ, Ryan ET, Hill DR, Solomon T, eds. Hunter's Tropical Medicine and Emerging Infectious Diseases. 9th ed. Philadelphia: Saunders; 2013:568-576.).
https://www.clinicalkey.com

Slide 12-15: Electron micrographs of *Salmonella* invading M-cells, and diagram of *Salmonella* pathogenesis, courtesy of Stanley Falkow and Denise Monack, Stanford University. Splenomegaly in mice infected by *Salmonella* Typhimurium courtesy of Denise Monack. Time lapse movie of macrophages courtesy of Manuel Amieva.
Slide 15: Typhoid Mary. Mary Mallon. Illustration that appeared in 1909 in The New York American
http://commons.wikimedia.org/wiki/File:Mallon-Mary_01.jpg

Slide 17: Intravenous antibiotics..
http://commons.wikimedia.org/wiki/File:ICU_IV_1.jpg

Slide 18: Live attenuated typhoid vaccine.
http://en.wikipedia.org/wiki/Ty21a

Slide 19: *Listeria monocytogenes* invading the tips of an intestinal villus. Courtesy of Manuel Amieva and Mickey Pentecost, Stanford University
http://www.plospathogens.org/article/info%3Adoi%2F10.1371%2Fjournal.ppat.1000900